

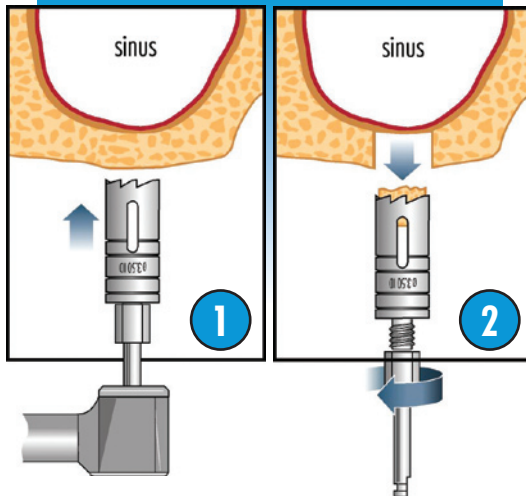
easyretrieve

Two-Piece Trepine Burs

TUTORIAL INTERNAL SINUS LIFT PROCEDURE UTILIZING TWO-PIECE TREPHINE

DEVELOPED BY DR. BURTON LANGER, DMD

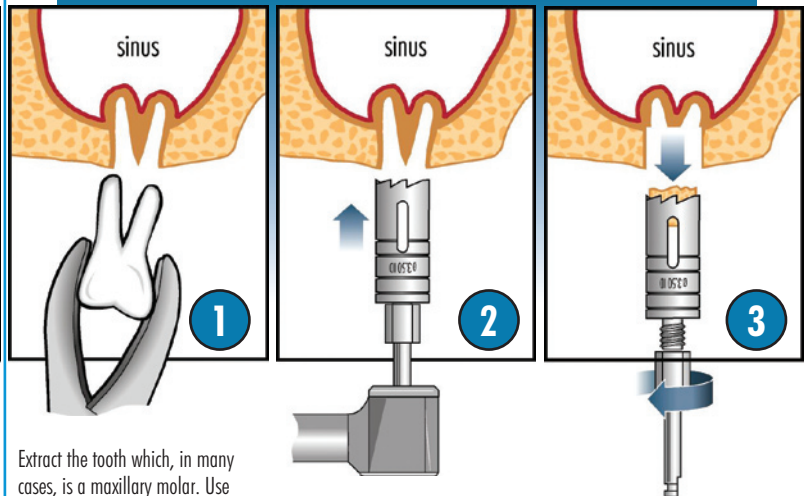
FROM A HEALED SITE



Instead of starting the osteotomy with graduated drills, start with a 3.50mm I.D. trephine. Start in reverse to minimize chatter, going forward in 2mm increments.

As the trephine comes close to the sinus membrane, use slow speed — no water. Remove the trephine.

FROM FRESH EXTRACTION SITE

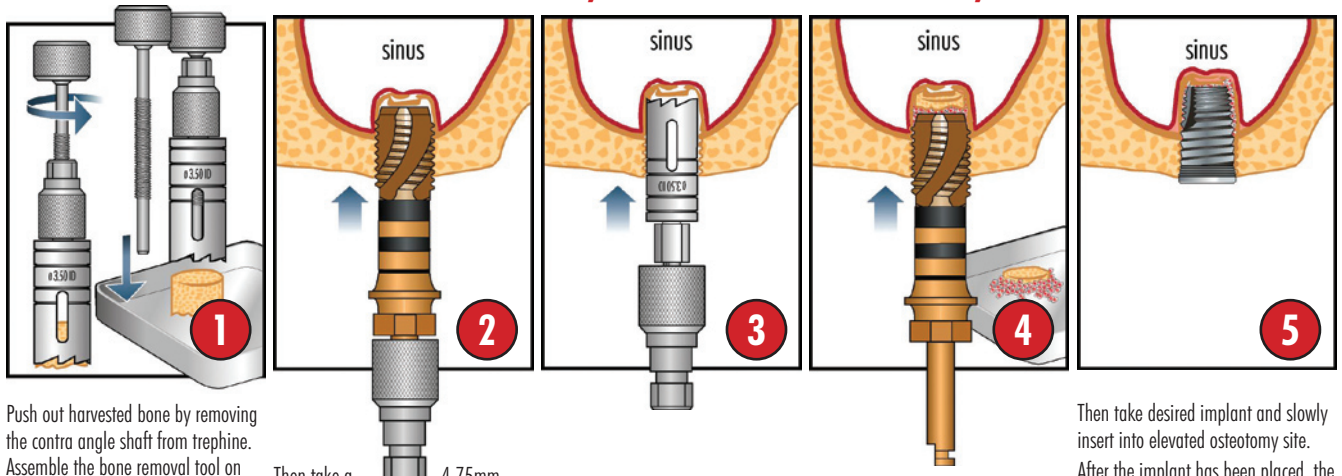


Extract the tooth which, in many cases, is a maxillary molar. Use the least traumatic technique, such as dividing the tooth into three sections, and remove each root separately so as not to damage the interproximal or labial plate of bone. Periostomes may be used.

Instead of starting the osteotomy with graduated drills, start with a 3.50mm I.D. trephine. Start in reverse to minimize chatter, going forward in 2mm increments.

As the trephine comes close to the sinus membrane, use slow speed — no water. Remove the trephine.

REMOVE BONE FROM TREPHINE, LIFT SINUS MEMBRANE, PLACE IMPLANT



Push out harvested bone by removing the contra angle shaft from trephine. Assemble the bone removal tool on the trephine and slowly turn plunger knob to push bone out. Use a sterile bowl to gather the harvested bone for re-use.*

Then take a 4.75mm tap and try to elevate the bone and sinus membrane. If there is resistance, go back and use the trephine again. Repeat until you see the tap going apically. Again slow speed — no water.

Increase the elevation with the trephine to the desired depth.

Insert the bone core and again use tap, but only in 1-2mm increments.

Then take desired implant and slowly insert into elevated osteotomy site. After the implant has been placed, the areas where the socket existed should be grafted with the bone graft material of your choice if necessary. The area should be covered with tissue in an attempt to achieve primary closure.

* Sharan, Abrel. Maxillary Sinus Pneumatization Following Extractions: A Radiographic Study, Int J Oral Maxillofac Implants 2008;23:48-56